

Case Report: Virtual MR Bronchoscopy in the Fetus*

Heron Werner^{1,4}; Pedro Daltro^{1,4}; Thomas M. Doring^{1,2,4}; Marcio Bernardes^{1,2}; Jorge R. Lopes dos Santos³; Ricardo Fontes³; Simone Belmonte²; Romeu Cortes Domingues^{1,2}

¹*Clínica de Diagnóstico por Imagem (CDPI, DASA), Rio de Janeiro, Brazil*

²*Clínica Multiimagem (MI, DASA), Rio de Janeiro, Brazil*

³*Instituto Nacional de Tecnologia (INT), Rio de Janeiro, Brazil*

⁴*Department of Radiology, Universidade Federal do Rio de Janeiro (UFRJ), Rio de Janeiro, Brazil*

Objective

To show magnetic resonance imaging (MRI) with virtual bronchoscopy (VB) in the evaluation of fetal airway patency.

Introduction

'Virtual bronchoscopy' is a technique that involves the creation and evaluation of representations of the bronchial tree and surrounding structures using spatial information derived from imaging modalities other than the bronchoscope itself [1]. Initially, these two-dimen-

sional and later three-dimensional (3D) bronchial tree representations were generated from computed tomography images. However, VB can now also be performed using data from MRI. There are several software programs available to help generate accurate and realistic

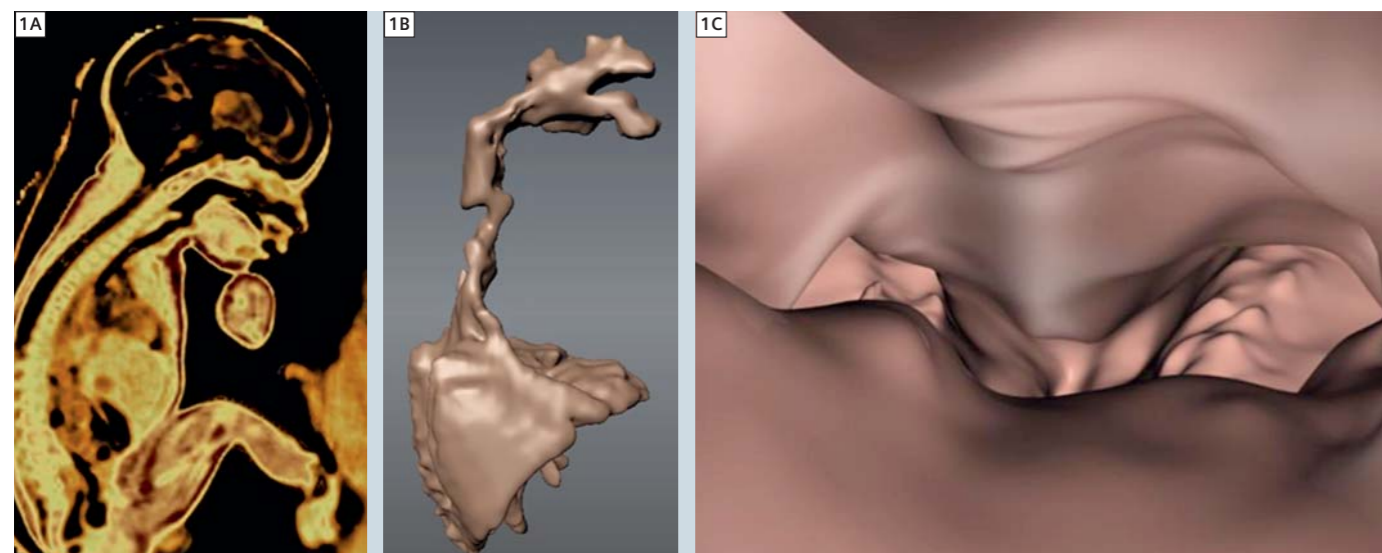
renderings of the bronchial tree [3, 4]. MR images are a prerequisite to obtain good quality images of the airway paths of the fetus. MRI is used to generate a 3D model of the airway; in most cases volume rendering techniques (VRT) are used and do also allow interactive fly through e.g. for intervention planning. In addition, VB based on MRI provides additional information about anatomy beyond the airway wall is important for therapy planning e.g. or surgery. The development of imaging technology has led to vast improvements in fetal evaluation. The primary method of fetal assessment is the ultrasound examination because it is effective, patient-friendly, cost-efficient and considered to have no collateral effects [2]. When ultrasound cannot provide sufficiently high-quality images or further (functional) information is required, MRI is

used. Its high-resolution with excellent contrast fetal imaging allows visualization of internal tissues to be realized [5]. In this article we describe how VB was performed in both a normal fetus that underwent MRI at 28 weeks gestation due to placenta previa with suspicion of placenta accrete, and also in a 37 week fetus with cervical teratoma.

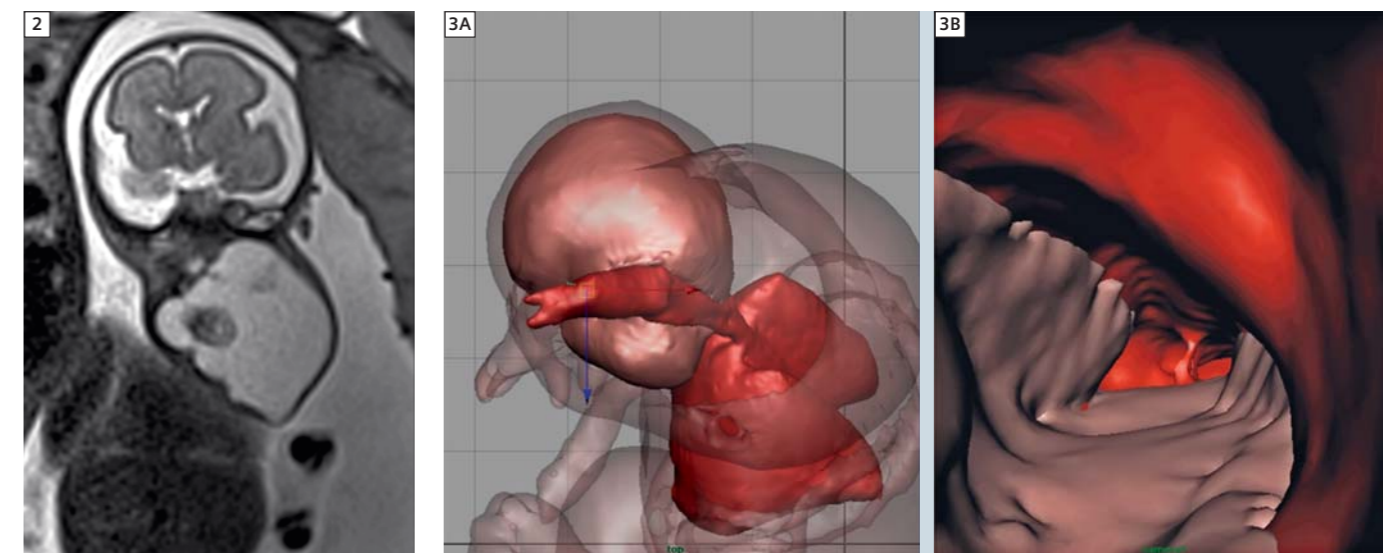
Methods

MRI examination was performed using a 1.5T scanner (MAGNETOM Avanto, Siemens Healthcare, Erlangen, Germany). The protocol involved a T2-weighted single shot Turbo Spin Echo sequence in the three planes of the fetal body (HASTE; shortest repetition time (TR); echo time (TE) 140 ms; field-of-view 300–200 mm; matrix 256×256; slice thickness 4 mm; acquisition time 17 s; 40 slices). In addition, we applied a

3D T2-weighted balanced steady state sequence (TrueFISP) in the sagittal plane (TRUFI; TR 3.02 ms; TE 1.34 ms; voxel size 1.6×1.6×1.6 mm³; flip angle 70°; parallel acquisition PAT factor 2; acquisition time, 0.26 s). The entire examination time was less than 20 minutes. The 3D MRI datasets were reconstructed to produce an interactive surface model of the fetal respiratory tract that could be viewed from any angle. First, a 3D model of the fetal airway was created from the overlapping image layers generated by MRI using the Mimics software (Materialise, Leuven, Belgium), which allowed the surface of the airway to be delineated using contrast detection in the relevant areas of interest. The 3D model thereby generated was exported using the standard triangular language file format and then converted into an OBJ file using the MAYA 3D modeling



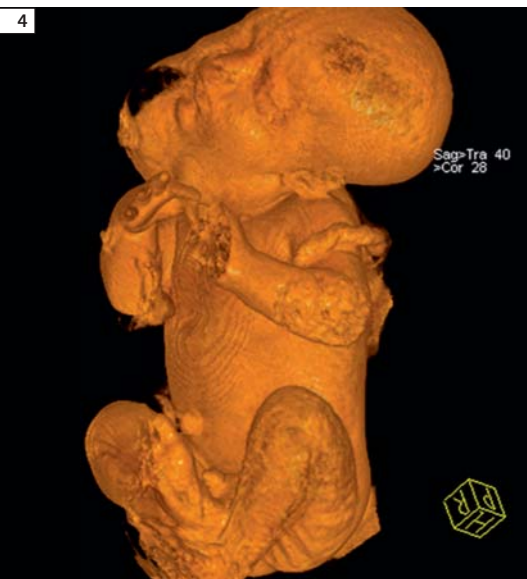1 Post-processing sequence TrueFISP 3D (1A), a volume rendering (thin VRT) thickness of 1.8 mm. 3D view of the lungs with airway paths (sagittal view, 1B) and virtual bronchoscopic image of normal carina and mainstem bronchi (1C).



2 T2-weighted sequence (coronal view) of the fetus (28 weeks) with teratoma.

3 (3A) 3D reconstruction showing the teratoma and its relationship to the upper airway, trachea and lung as well as virtual fly-through (3B).

*MR scanning has not been established as safe for imaging fetuses and infants under two years of age. The responsible physician must evaluate the benefits of the MRI examination compared to other imaging procedures.



4 3D view of the fetus obtained by TrueFISP 3D.

software (Autodesk, San Rafael, CA, USA) [6, 7]. This program allows the virtual positioning of observation cameras while working with multiple on-screen windows. Since the development of the 3D model, the software has allowed the user to determine the best positioned viewpoints for visualization of the 3D model and also facilitated the adjustment of lighting parameters to improve contrast resolution. Using the navigation mode it is also possible to perform virtual bronchoscopy to visualize the upper respiratory tract from the pharynx downwards through the tracheobronchial tree with a quality similar to that obtainable by videotaped bronchoscopy.

Results

There were two main outcomes: the possibility of creating 3D virtual airway paths from fetuses with cervical tumors, and the carrying out of VB based on those images. After delivery of the child and based on VB, a complete resection of the teratoma was conducted.

Conclusion

It was demonstrated that MRI data can be used to create a 3D model of the respiratory tract in a normal and abnormal fetus. We believe that this technique could become a useful tool for the assessment of fetal airway patency.

References

- 1 Ferguson JS, McLennan G. Virtual bronchoscopy. Proc Am Thorac Soc. 2005; 2: 488–491.
- 2 Frates M, Kumar AJ, Benson CB, Ward VL, Tempny CM. Fetal anomalies: comparison of MR imaging and US for diagnosis. Radiology 2004; 232: 398–404.
- 3 Lam WW, Tam PKH, Chan FL, Chan K, Cheng W. Esophageal atresia and tracheal stenosis: Use of three-dimensional CT and virtual bronchoscopy in neonates, infants, and children. AJR 2000; 174: 1009–1012.
- 4 Merritt SA, Gibbs JD, Yu KC, Patel V, Rai L, Cornish DC, Bascom R, Higgin WE. Image-guided bronchoscopy for peripheral lung lesions. Chest 2008; 134: 1017–1026.
- 5 Prayer D, Brugger PC, Prayer L. Fetal MRI: techniques and protocols. Pediatr Radiol 2004; 34: 685–693.
- 6 Werner H, Dos Santos JRL; Fontes R, Daltro P, Gasparetto E, Marchiori E, Campbell S. Virtual bronchoscopy in the fetus. Ultrasound Obstet Gynecol 2011; 37: 113–115.
- 7 Werner H, Dos Santos JRL; Fontes R, Daltro P, Gasparetto E, Marchiori E, Campbell S. Additive manufacturing models of fetuses built from three-dimensional ultrasound, magnetic resonance imaging and computed tomography scan data. Ultrasound Obstet Gynecol 2010; 36: 355–361.

Contact

Heron Werner
Clínica de Diagnóstico
por Imagem (CDPI, DASA)
Rio de Janeiro
Brazil
heron.werner@gmail.com

Expert Talks

Don't miss the talks of experienced and renowned experts covering a broad range of MRI imaging



Dynamic 3D MRA – Clinical Concepts
(syngo TWIST)

Jörg Barkhausen, M.D.
University Hospital, Essen



Clinical Applications of Arterial Spine Labeling
(syngo ASL)

John A. Detre, M.D.
University of Pennsylvania



Clinical Applications of Diffusion-Tensor Imaging
(syngo DTI)

Tammie L. S. Benzinger, M.D., Ph.D.
Washington University School of Medicine



Breast Cancer Management – Cross Modality Approach

John F. Nelson, M.D.
Battlefield Imaging



MRI in Sports Medicine

John A. Carrino, M.D., M.P.H
Johns Hopkins University, School of Medicine

Visit us at www.siemens.com/magnetom-world
Go to **Education > e-trainings & Presentations**